



# Optic coherence tomography evaluation of macula after external beam radiotherapy

Evaluation of macula after external beam radiation

Neslihan Kurtul<sup>1</sup>, Gökhan Özdemir<sup>2</sup>, Necla Gürdal<sup>1</sup>, Ayşegül Çömez<sup>2</sup>

<sup>1</sup>Department of Radiation Oncology, <sup>2</sup>Department of Ophthalmology, Faculty of Medicine, Sutcu Imam University, Kahramanmaraş, Turkey

*This study presented as an oral presentations at 13<sup>th</sup> National Radiation Oncology Congress, 27April-1May 2018, Cyprus.*

## Abstract

**Aim:** In this study, we aimed to investigate the optic coherence tomography findings in patients who received external beam radiotherapy. **Material and Method:** All consecutive subjects applied to the radiation oncology department due to head, neck or brain tumors were enrolled prospectively into the study. Macula radiation dose and eye dose were calculated from dose-volume histogram plot curve. Eyes were evaluated with regard to macular thickness with optical coherence tomography at the baseline and 6th month after the radiotherapy. **Results:** A total of 32 eyes of 16 patients were included in the study. The mean macula dose was  $1780 \pm 1403$  cGy, maximum macula dose was  $2059 \pm 1479$  cGy and the mean eye dose was  $1015 \pm 784$  cGy. Among 16 patients, macular edema was developed in one patient (%6,25) 18 weeks after the radiotherapy. Apart from this patient, no other patient developed any kind of retinal complication regarding the radiotherapy during 6 months follow up. The retina showed no change with regard to the studied parameters during the study period ( $p < 0.05$ ). **Discussion:** OCT is an effective way to determine early changes in patients undergoing radiotherapy and it enables prompt diagnosis of early clinical macular edema. This study is of significance in that our patients didn't get direct retinal radiation therapy during 6-months follow-up. Long-term studies with a larger cohort group will yield more suggestive data on this clinical entity.

## Keywords

Macula; Optical Coherence Tomography; Radiotherapy

DOI: 10.4328/JCAM.6002 Received: 11.08.2018 Accepted: 12.09.2018 Published Online: 17.09.2018 Printed: 01.01.2019 J Clin Anal Med 2019;10(1): 113-6  
Corresponding Author: Neslihan Kurtul, Department of Radiation Oncology, Sutcu Imam University Faculty of Medicine, Avsar Campus, Kahramanmaraş, Turkey.  
GSM: +905067872841 E-Mail: drneslihankurtul@gmail.com  
ORCID ID: 0000-0001-9173-6280

Introduction

Radiation retinopathy (RR) may result from direct radiation treatment of the malignancies of the head and neck region and was first described by Stallard in 1933 [1]. It has been reported after plaque brachytherapy as well as after radiotherapy due to intracranial tumors and orbital diseases [2,3]. It generally develops between six months and three years after radiation exposure but it can develop as early as one month and as late as 15 years or more [4]. The disease is characterized by delayed retinal hemorrhages, macular edema, retinal microvascular changes, capillary occlusion, endothelial cell loss, microaneurysm formation, perivascular sheathing, and neovascularization. Macular edema involving the fovea is a major source of visual morbidity in patients undergoing radiation retinopathy [5]. Previous studies have reported different rates of macular ischemia up to 76% [6].

Optical coherence tomography (OCT) and fundus fluorescein angiography are important diagnostic tools in the evaluation of eyes with RR. OCT is a noninvasive procedure that directly images retinal cross-sections and various retinal diseases such as macular degeneration, macular edema, and optic nerve disorders. It also gives numeric data about the ocular structures and enables quantitative evaluation of macular anatomy. Researches showed that OCT can detect evidence of macular edema 5 months earlier before clinically detectable radiation maculopathy is established [7].

Patients with orbital tumors treated with plaque or brachytherapy are required to undergo ophthalmological examination routinely but patients treated with external beam radiotherapy are less likely to be evaluated regularly with dilated fundus examinations. Considering the progressive pathophysiology and latency of RR, early visits after radiotherapy may be inadequate and subsequent delays in diagnosis and treatment can result in long-term maculopathy leading to irreversible vision loss [5]. It is crucial that regular visits should be scheduled after external beam radiotherapy for the prompt detection of radiation retinopathy.

Ophthalmic armamentarium including OCT may help early detection of the manifestations of radiation retinopathy and be an important asset in the diagnosis. In this paper, we prospectively investigated optic coherence tomography findings in patients received external beam radiotherapy to the periorbital region.

Material and Method

Patients

The study followed the tenets of the Declaration of Helsinki and all participants gave written informed consent for the study. The study was approved by the Kahramanmaraş Sutcu Imam University clinical research ethics committee. All consecutive subjects applied to the radiation oncology polyclinic due to head and neck tumors or brain tumors were enrolled prospectively into the study. Subjects with short survival rates or poor health status who were unable to conform to study protocol procedures, patients with comorbid diseases such as diabetes mellitus, coronary artery diseases, and hypertension or patients with any ocular diseases were excluded from the study. All patients underwent a complete ophthalmologic evaluation including dilated funduscopy examination. Patients were followed

up for 6 months and at the end of 6th month, the study was finished.

Radiation therapy

All subjects were applied thermoplastic masks and requested to close eyelids for protection during the Simulation CT and radiotherapy. Simulation CT sections were taken at a thickness of 2.5 mm and the computerized tomography images were then transferred to the Eclipse treatment planning system (Varian Medical Systems, Version 13.0, Inc. Palo Alto, CA). Macula was defined as the area 4-6 mm temporal to the optic disc over three planes and planned risk volume margin was defined as 2 mm. Radiotherapy of 6 MV photon energy was applied with a linear accelerator (Trilogy, Varian Medical Systems Palo Alto, CA) at a fraction dose of 1.8/2 Gy daily. Macula radiation dose and globe dose were calculated from dose-volume histogram plot curve.

OCT

Eyes were evaluated with regard to macular thickness with OCT at the baseline and 6th month after the radiotherapy. The macular structure was evaluated using an OCT (Cirrus HD-OCT, Zeiss, Jena, Germany) using a scan pattern of 512 × 128. A macular cube of 6x6 mm was measured. The macular thickness between the inner limiting membrane and retinal pigment epithelium in 9 sectors originating from the Early Diabetic Retinopathy Study Group were determined (Figure 1,2).

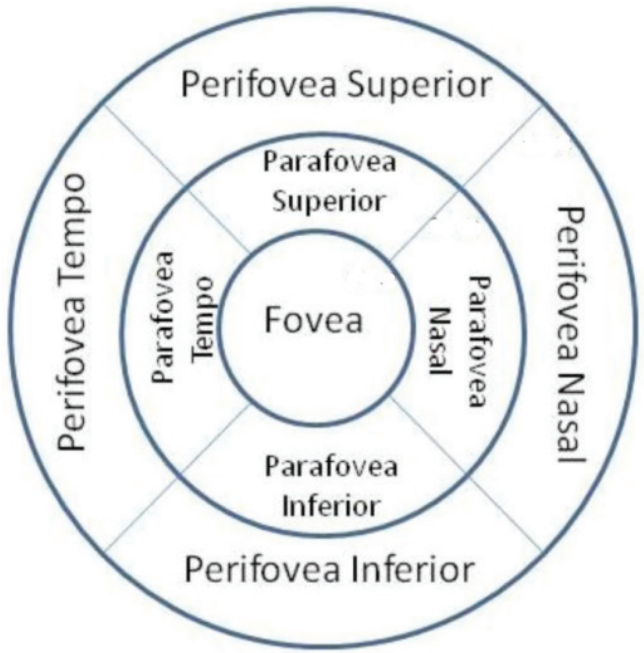


Figure 1. 6x6 mm macular cube involving nine sectors

Statistics

Statistical analyses were calculated with a statistical software program (SPSS ver.22, IBM, Chicago Ill). The data were expressed as the mean ± standard deviation. The paired t-test was used to compare the significances between the measurements after the normality of distribution was assessed by the Shapiro-Wilk test. The p-value of less than 0.05 was set as the significance level.

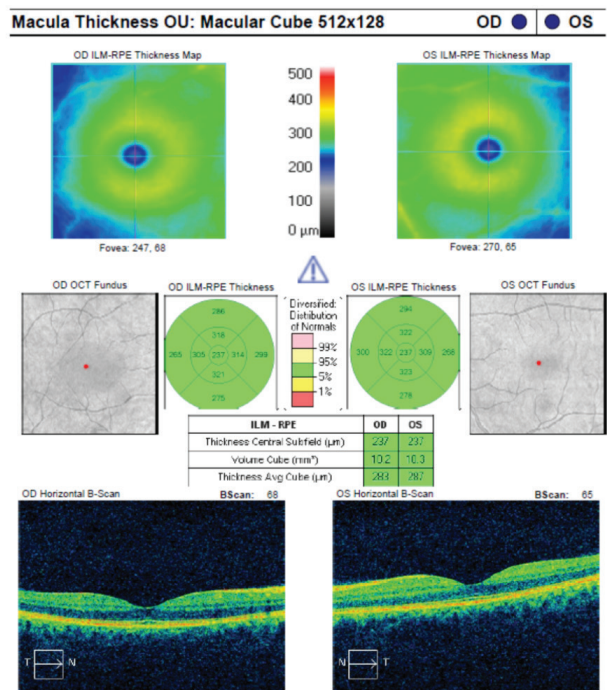


Figure 2. The OCT Picture of a patient before radiotherapy

Results

A total of 32 eyes of 16 patients were included in the study. Of subjects, 13 (81.3%) were male and 3 (18.8%) were female. The mean age of the subjects was 51 years (19-76 years). The tumor was located in the nasopharynx in 4 patients, in the oral cavity in 2 patients and in the central nervous system in 10 patients (4 glioblastoma multiforme, 2 low-grade glial tumors, 1 ependymoma, 1 anaplastic meningioma, 1 medulloblastoma and 1 primary CNS lymphoma). Nine subjects (56.3%), received radiotherapy and chemotherapy simultaneously. As chemotherapy, 6 patients received cisplatin and 3 patients received temozolomide. The mean macula dose was  $1780,53 \pm 1403,00$  cGy, maximum macula dose was  $2059,10 \pm 1479,96$  cGy and the mean orbital dose was  $1015,33 \pm 784,52$  cGy. Macular thickness and volume values in response to radiotherapy are listed in Table 1. Among 16 patients, radiation retinopathy characterized by visual loss, macular edema hemorrhage, increased vascular tortuosity, fibrous traction bands, and hard exudates was developed in one patient (%6,25) 18 weeks after the radiotherapy. In the patient with developed bilateral radiation retinopathy,the mean macular radiation dose was 3727 cGy in the right eye and 3618 cGy in the left eye and the maximum macular radiation dose was 4014 cGy in the right eye and 3983 cGy in the left eye, the mean eye glob radiation dose was 2442 cGy on the right side and 2186 cGy on the left side. Due to the perpetuating macular edema and visual loss, the patient was treated with intravitreal anti-vascular endothelial growth factor drug injections after which the edema was treated successfully. To give a clear idea of how radiotherapy affects retina other than vasculopathy driven edema, analyses were done after the patient with macular edema was excluded. Apart from this patient, no other patient developed any kind of retinal complication regarding the radiotherapy during 6 month follow up. There was

no difference between the studied parameters and any kind of retinopathy didn't develop during the study period ( $p<0.05$ ).

Table 1. Macula volume and the thicknesses in 9 sectors before and 6 months after the radiotherapy. (n=30)

|                                    | Baseline<br>measure-<br>ment<br>(Mean±Std<br>Dev) | Measure-<br>ment 6<br>months after<br>radiotherapy<br>(Mean±Std<br>Dev) | p     |
|------------------------------------|---|---|-------|
| Macular cube (6x6 mm) volume (mm³) | 10,1  | 10,2  | 0,484 |
| Subfoveal thickness thickness (μ)  | 252,0 ±21,7                                       | 253,1 ±19,9   | 0,793 |
| Parafovea superior thickness (μ)   | 324,8 ±15,3                                       | 324,5 ±17,2   | 0,913 |
| Parafovea temporal thickness (μ)   | 320,0 ±15,6                                       | 317,2 ±21,7   | 0,483 |
| Parafovea nasal thickness (μ)      | 318,8 ±18,4                                       | 318,7 ±17,4   | 0,984 |
| Parafovea inferior thickness (μ)   | 322,8 ±12,6                                       | 316,1 ±41,4   | 0,327 |
| Perifovea superior thickness (μ)   | 279,7 ±10,9                                       | 284,6 ±14,8   | 0,067 |
| Perifovea temporal thickness (μ)   | 281,4 ±19,5                                       | 282,6 ±25,9   | 0,677 |
| Perifovea nasal thickness (μ)      | 280,4 ±24,0                                       | 280,3 ±16,1   | 0,957 |
| Perifovea inferior thickness (μ)   | 270,4 ±12,1                                       | 272,6 ±14,5   | 0,489 |

Discussion

Radiation retinopathy can be seen following plaque and external beam radiotherapy. Predisposing factors for radiation-induced retinal injury have been reported as a history of diabetes, collagen vascular disease, hypertension, and chemotherapy [8-10]. Due to the fact that RR displays clinical and angiographic features that are virtually identical to those seen in retinal vascular diseases, patients with a previous history of those diseases are excluded from the study [11]. Risk factors for RR are total radiation dose, fractionation, field design, type and rate of administration. Although the estimated tolerance dose with a 5% risk at 5 years (TD 5/5) is 45 Gy and the TD50/5 is 65 Gy, the threshold dose for the retina is thought to be between 30 Gy and 35 Gy [12]. In the recent Cochrane database review of radiotherapy for macular degeneration, no retinopathy or optic nerve damage was reported in 1154 patients treated with doses up to 24 Gy [13]. Hyperfractionation is associated with a decreased incidence of RR and patients who received fractions of <1.9 Gy are found unlikely to develop RR in one study [14]. Radiated volume is also a risk factor. Eyes receiving more than 50 Gy to 60% or more of the retina have been shown to be more likely to develop RR [15]. In this research, we found that radiotherapy induced macular edema in one patient but other 15 patients showed no evidence of retinopathy on OCT and ocular examination. In our study, in the patient who developed edema, craniospinal radiation was done and retina and macula were included in the target volume in craniospinal radiation therapy. We had to give a dose which was more than the thresholds that other studies reported as 24 Gy and 30-35 Gy. Finger et al. investigated the risk factors for radiation maculopathy after ophthalmic plaque radiation for choroidal melanoma and found that a significant dose-response relationship was found between dose to fovea and radiation maculopathy. As compared with a dose of < 35 Gy, the risk of RM was 1.74 (95% CI, 0.98 to 3.1) for doses from 35 to 70 Gy, and the risk of RM was 2.43 (95% CI, 1.48 to 4.0) for doses of 70 Gy or more [16]. In this respect, the macular dose may

be more valuable for predicting the radiation retinopathy. This result means that it would be prudent to contour the macula in addition to contouring the globe.

Although the latent period is typically between 6 months and 3 years and shorter after the high dose radiation, early onset cases can be found. In this research, macular parameters determined by OCT remained the same throughout the study in all patients but one patient in 6-month follow-up. In a case report, OCT demonstrated significant thinning of inner plexiform, inner nuclear and outer nuclear layers, suggesting that primary radiation-induced damage is initially confined to inner retinal layers [17]. Another study presented a radiation retinopathy case one month after total cranial radiotherapy [18]. The OCT of that patient revealed attenuation of central macular thickness with loss of photoreceptor inner segment/outer segment junction rather than macular edema.

Archer et al. found that the immediate effects of radiation are related to interphase and early mitotic death of injured endothelial cells whereas later changes may be attributed to the delayed mitotic death of compromised endothelial cells as they attempt to divide in the ordinary course of repair and replacement [19]. As a result, the chronic effects of radiation on the retina are retinal microvascular lesions, endothelial cell loss, capillary occlusion, and microaneurysm formation. Macular edema arising from microvascular changes is a common finding of RR.

In our study, we didn't record any kind of change in macular parameters. Longer follow-ups may be able to detect late changes caused by radiation. Mashayekhi et al. found that eyes with sub-clinical macular edema at the baseline and at the 4th month after plaque radiotherapy had a significantly higher rate of future clinical macular edema compared to the eyes without sub-clinical macular edema at baseline [20]. The authors suggested that high-risk patients for RR be evaluated with OCT and ocular examination 4 and 6 months after the radiotherapy.

In conclusion, OCT is an effective way to determine early changes in patients undergoing radiotherapy to the head and neck region and it enables convenient diagnosis of early clinical macular edema. Our study is also of significance in that our patients didn't get direct retinal radiation therapy. Long-term studies with a larger cohort group will yield more suggestive data on this clinical entity.

This study presented as an oral presentation at 13th National Radiation Oncology Congress, from 27 April to 1 May 2018, Cyprus.

#### Scientific Responsibility Statement

*The authors declare that they are responsible for the article's scientific content including study design, data collection, analysis and interpretation, writing, some of the main line, or all of the preparation and scientific review of the contents and approval of the final version of the article.*

#### Animal and human rights statement

*All procedures performed in this study were in accordance with the ethical standards of the institutional and/or national research committee and with the 1964 Helsinki declaration and its later amendments or comparable ethical standards. No animal or hu-*

*man studies were carried out by the authors for this article.*

**Funding:** None

#### Conflict of interest

*None of the authors received any type of financial support that could be considered potential conflict of interest regarding the manuscript or its submission.*

#### References

1. Stallard HB. Radiant energy as (a) a pathogenic and (b) therapeutic agent in ophthalmic disorders. Gifford Edmonds prize essay for. Br J Ophthalmol. 1933; 6 (Suppl): S1-126.
2. Archer DB. Responses of retinal and choroidal vessels to ionising radiation. Eye 1993;7(1):1. DOI: 10.1038/eye.1993.3
3. Durkin SR, Roos D, Higgs B, Casson RJ, Selva D. Ophthalmic and adnexal complications of radiotherapy. Acta Ophthalmol Scand. 2007; 85(3): 240-50. DOI: 10.1111/j.1600-0420.2006.00822.x
4. Ahmet Kaan Gündüz CLS. Radiation Retinopathy and Papillopathy. In: Myron Yanoff JSD editor. Ophthalmology: Elsevier Health Sciences. 2014.p.565.
5. Leigh Spielberg PDP, Anita Leys. Radiation Retinopathy. In: Ryan's Retina Elsevier. 2017. p.1219.
6. Kinyoun JL. Long-term visual acuity results of treated and untreated radiation retinopathy (an AOS thesis). Trans Am Ophthalmol Soc. 2008; 106: 325.
7. Horgan N, Shields CL, Mashayekhi A, Teixeira LF, Materin MA, Shields JA. Early macular morphological changes following plaque radiotherapy for uveal melanoma. Retina. 2008; 28(2): 263-73. DOI: 10.1097/IAE.0b013e31814b1b75.
8. Packer S, Rotman M. Radiotherapy of choroidal melanoma with iodine-125. Ophthalmology. 1980; 87(6): 582-90. DOI: 10.1016/S0161-6420(80)35194-4
9. Wakelkamp IM, Tan H, Saeed P, Schlingemann RO, Verbraak FD, Blank LE, et al. Orbital irradiation for Graves' ophthalmopathy: Is it safe? A long-term follow-up study. Ophthalmology. 2004; 111(8): 1557-62. DOI: 10.1016/j.ophtha.2003.12.054
10. Chan RC, Shukovsky LJ. Effects of irradiation on the eye. Radiology. 1976; 120(3): 673-5. DOI: 10.1148/120.3.673
11. JDM Gass. Stereoscopic atlas of macular diseases, diagnosis and treatment. In: Mosby SL editor. Stereoscopic atlas of macular diseases, diagnosis and treatment. 1987. p.404-5.
12. Emami B, Lyman J, Brown A, Cola L, Goitein M, Munzenrider J, et al. Tolerance of normal tissue to therapeutic irradiation. Int J Radiat Oncol Biol Phys. 1991; 21(1): 109-22. DOI: 10.1016/0360-3016(91)90171-Y
13. Evans JR, Sivagnanavel V, Chong V. Radiotherapy for neovascular age-related macular degeneration. Cochrane Database Syst Rev. Rev 2010; 5(5): DOI: 10.1002/14651858.
14. Parsons JT, Bova FJ, Fitzgerald CR, Mendenhall WM, Million RR. Radiation retinopathy after external-beam irradiation: analysis of time-dose factors. Int J Radiat Oncol Biol Phys. 1994; 30(4): 765-73.
15. Takeda A, Shigematsu N, Suzuki S, Fujii M, Kawata T, Kawaguchi O, et al. Late retinal complications of radiation therapy for nasal and paranasal malignancies: relationship between irradiated-dose area and severity. Int J Radiat Oncol Biol Phys. 1999; 44(3): 599-605. DOI: 10.1016/S0360-3016(99)00057-7
16. Finger PT, Chin KJ, Yu G-P, Group P-FCMS. Risk factors for radiation maculopathy after ophthalmic plaque radiation for choroidal melanoma. Am J Ophthalmol. 2010; 149(4): 608-15. DOI: 10.1016/j.ajo.2009.11.006.
17. Raman R, Pal SS, Krishnan T, Laxmi G, Radke N, Sharma T. High-resolution optical coherence tomography correlates in ischemic radiation retinopathy. Cutan Ocul Toxicol. 2010; 29(1): 57-61. DOI: 10.3109/15569520903331674.
18. Hsu C-R, Tai M-C, Chang Y-H, Chien K-H. Rapid onset of radiation maculopathy after whole-brain radiation therapy: A case report. Medicine. 2016; 95(39): DOI: 10.1097/MD.0000000000004830.
19. Archer D, Amoaku W, Gardiner T. Radiation retinopathy—clinical, histopathological, ultrastructural and experimental correlations. Eye. 1991; 5(2): 239. DOI: 10.1038/eye.1991.39
20. Mashayekhi A, Schönbach E, Shields CL, Shields JA. Early subclinical macular edema in eyes with uveal melanoma: association with future cystoid macular edema. Ophthalmology. 2015; 122(5): 1023-9. DOI: 10.1016/j.ophtha.2014.12.034

#### How to cite this article:

Kurtul N, Özdemir G, Gürdal N, Çömez A. Optic coherence tomography evaluation of macula after external beam radiotherapy. J Clin Anal Med 2019;10(1): 113-6.